

Exploring minimally invasive options: Laparoscopic transabdominal levator transection for low rectal cancers

Fadl H. Veerankutty, Sidharth Chacko, Vipin I. Sreekumar, Prasad Krishnan, Deepak Varma, Prakash Kurumboor

Department of GI and HPB Surgery, Aster Medcity, Kochi, Kerala, India

Abstract

Extralevator abdominoperineal excision (ELAPE) of the rectum offers wider circumferential margin and decreased rate of intraoperative tumour perforation. However, the need to change the position of the patient in between abdominal and perineal stages of the procedure and extended perineal resection result in increased morbidity and operative time. Evolving technique of laparoscopic transabdominal controlled division of levator ani muscles under direct vision could address these issues while providing all benefits of ELAPE for patients with low rectal cancers.

Keywords: Abdominoperineal resection, extralevator, laparoscopy, rectal cancer, total mesorectal excision

Address for correspondence: Dr. Fadl H. Veerankutty, Department of GI and HPB Surgery, Aster Medcity, Kochi, Kerala, India.

E-mail: fadl_05@yahoo.com

Received: 22.05.2018, **Accepted:** 23.05.2018

INTRODUCTION

Extralevator abdominoperineal excision (ELAPE) of the rectum was proposed by Holm *et al.* to circumvent the high circumferential resection margin positivity rate related to conventional abdominoperineal excision of the rectum (CAPER).^[1] The concept is based on the principle that enables the division of levators laterally at their point of attachment to the pelvic bony–ligamentous ring, avoiding dissecting the mesorectum off the levator ani muscle, thus minimising the chance of breaking into tumour and waisting of the specimen.^[2]

However, ELAPE is associated with increased operative duration as it needs change of patient position from lithotomy to prone for the perineal procedure. Wide perineal wound defect increases morbidity of the procedure and often demands reconstruction with help of plastic surgeons. Laparoscopic transabdominal controlled division

of levator ani muscles under direct vision (LT-ELAPE) has been developed to counter the difficulties associated with ELAPE.^[3,4]

PRE-OPERATIVE PREPARATION

Pre-operative marking of the stoma site and stoma care education is done by trained stomatherapists for all patients. No bowel preparation is given preoperatively. All patients receive single dose of intravenous antibiotics preoperatively.

POSITIONING OF PATIENT AND PLACEMENT OF PORTS

Patient position is similar to conventional laparoscopic APER. Patients are placed in modified lithotomy position with minimal flexion at the hips, keeping the thighs relatively level with the rest of the body. Special attention is given to ensure that patient is well strapped to the operating table.

This is an open access journal, and articles are distributed under the terms of the Creative Commons Attribution-NonCommercial-ShareAlike 4.0 License, which allows others to remix, tweak, and build upon the work non-commercially, as long as appropriate credit is given and the new creations are licensed under the identical terms.

For reprints contact: reprints@medknow.com

How to cite this article: Veerankutty FH, Chacko S, Sreekumar VI, Krishnan P, Varma D, Kurumboor P. Exploring minimally invasive options: Laparoscopic transabdominal levator transection for low rectal cancers. J Min Access Surg 2019;15:174-6.

| Access this article online | |
|---|--|
| Quick Response Code: | Website: www.journalofmas.com |
|  | DOI: 10.4103/jmas.JMAS_130_18 |

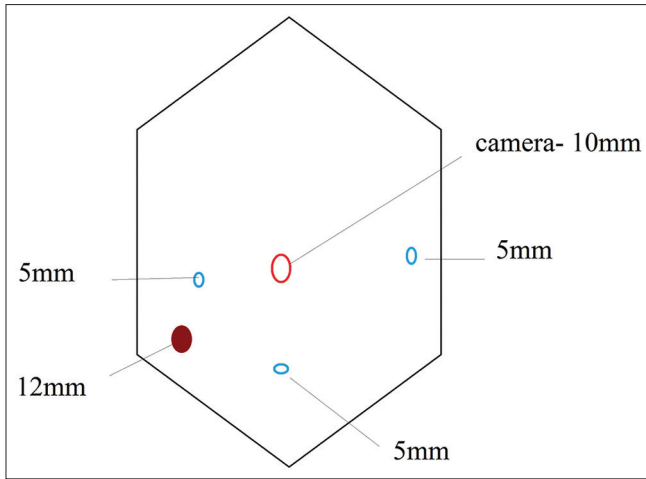


Figure 1: Our routine port positions: Right 5 and 12 mm are working ports. Left 5-mm port is used for retraction of the colon. An additional suprapubic port is placed for retraction of the colonic mesentery during left Toldt's fossa dissection, and for retraction of the peritoneal fold and rectum during pelvic part of the surgery

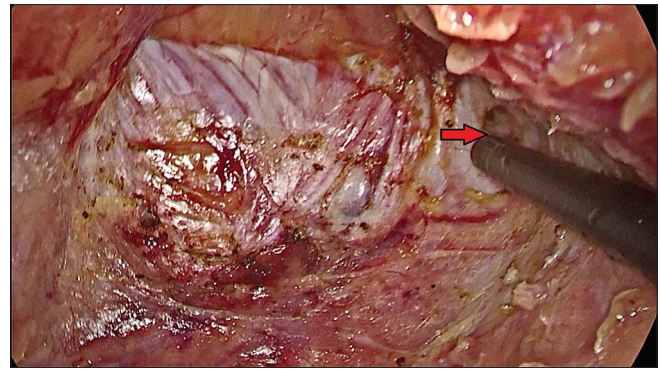


Figure 2: The levator transection begins by cutting the tendinous arch at 3 to 4 o'clock position (red arrow)

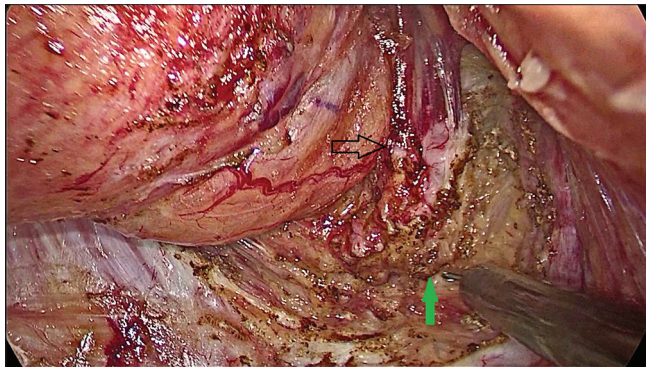


Figure 3: As the dissection proceeds, the incision on the levator is extended posteriorly (green arrow) and towards the left

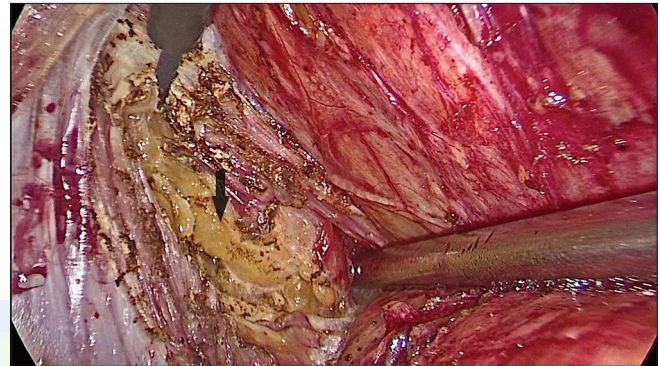


Figure 4: Ischiorectal fatty tissue is visualised on the left side (black arrow) after cutting through the tendinous arch of the levator muscle

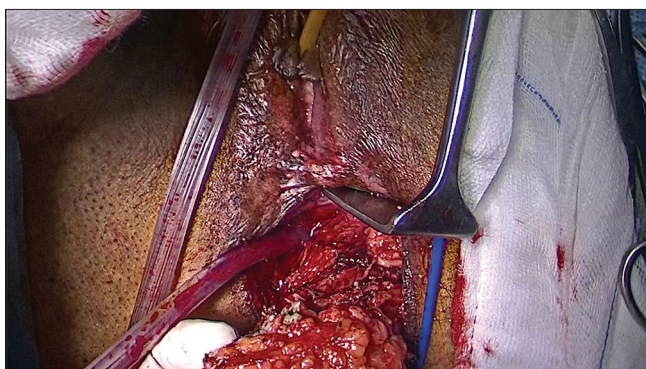


Figure 5: The specimen is separated from the vaginal wall and is being delivered out of the perineal wound

Operative table is manipulated to get a steep head-down position and a 15° left tilt to displace small bowel loops from the operative field. The surgeon stands at patient's right side, the first assistant at the left and the cameraman at patient's cranial end on the right. Initial access is

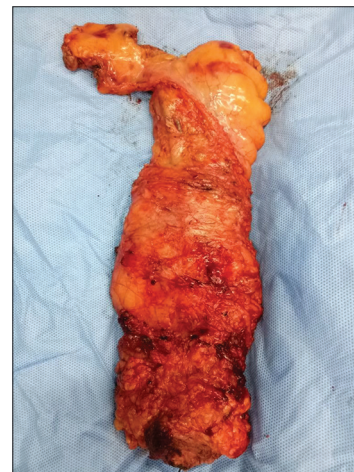

Figure 6: Cylindrical specimen without any surgical waist

obtained through the umbilicus using open technique. Figure 1 demonstrates our routine port positions. Pneumoperitoneum is established, and a pressure of 15 mmHg is maintained. An additional suprapubic port is placed for retraction of the colonic mesentery during left Toldt's fossa dissection, and for retraction of the peritoneal fold and rectum during pelvic part of the surgery.

OPERATIVE STEPS

Abdomen

The sigmoid colon is lifted anterolaterally by the assistant so that the root of sigmoid mesocolon is nicely exposed. The sigmoid colon is mobilised using medial to lateral approach. The left Toldt's space is dissected with meticulous application of traction and counter traction. We prefer high ligation of the inferior mesenteric artery taking special care to preserve sympathetic nerves. Lateral mobilisation is completed as in CAPER.

Pelvic part

Posterior dissection

Once colonic mobilisation is complete, the mesorectum is mobilised to the edge of the sacropromontory with special attention taken to protect ureters and pelvic autonomic nerves. The dissection is continued till the pelvic floor through Holey plane following principles of total mesorectal excision (TME). As the posterior dissection is continued, the apex of the coccyx bone comes into the view. The anococcygeal ligament can be clearly seen and is cut under direct visualisation.

Lateral and anterior dissection

Posterior dissection plane is extended bilaterally along the pelvic side walls following principles of TME. Contrary to the conventional APER, TME is terminated at the level of tendinous arch of levators instead of creating a plane between mesorectum and levator muscles. Anteriorly, the peritoneum is incised just above the peritoneal reflection. In males, the rectum is dissected away from seminal vesicles and prostate, and in females, the vagina is dissected away from the rectum.

Levator transection

We begin the levator transection at 3–4 o' clock position [Figure 2] extending the incision posteriorly and towards left [Figure 3]. Incision is deepened through the tendinous arch of the levator cutting the muscle until the ischiorectal fatty tissue is visualised [Figure 4]. Incision on the levator is extended laterally on both sides until ischiorectal fatty tissue is seen throughout.

Once the levator transection is complete, the sigmoid colon is transected with a linear stapler, and an end colostomy is created at the previously marked site. A 24 Fr Foley catheter is kept as a drain in the pelvis.

Perineal procedure

As the majority of pelvic dissection is already accomplished transabdominally, this part is comparatively easy. An elliptical incision is placed around the anus after closing it by a purse-string suture as in CAPER. The dissection plane is

deepened, and the pelvic plane is initially met posteriorly. Anteriorly, the specimen is separated from the lower posterior vaginal wall in females and prostate in males [Figure 5]. The extracted specimen is devoid of 'surgical waist' [Figure 6]. Perineal incision is closed primarily.

Oral feeds can be resumed once stoma starts functioning. Patient is discharged on post-operative day 4 or 5.

DISCUSSION

The rate of local recurrence is reportedly higher for CAPER than for anterior resection due to increased circumferential margin positivity.^[5] ELAPE has been suggested to address the poor outcome that may follow CAPER. ELAPE is also associated with lower incidence of intraoperative tumour perforation.^[6] However, many surgeons are hesitant to adopt ELAPE as it is associated with higher rate of perineal wound complications and increased operative duration. LT-ELAPE reduces operative time significantly as patient position change is not needed during the procedure. Perineal wound morbidity is relatively less as most of the pelvic dissection is done transabdominally. Pelvic autonomic nerve preservation may also be better as laparoscopy offers excellent visualisation of these structures. As the trainees also share the same view of chief surgeons, LT-ELAPE has an educational advantage over CAPER.

Financial support and sponsorship

Nil.

Conflicts of interest

There are no conflicts of interest

REFERENCES

1. Holm T, Ljung A, Häggmark T, Jurell G, Lagergren J. Extended abdominoperineal resection with gluteus maximus flap reconstruction of the pelvic floor for rectal cancer. *Br J Surg* 2007;94:232-8.
2. Shihab OC, Heald RJ, Holm T, How PD, Brown G, Quirke P, *et al.* A pictorial description of extralevator abdominoperineal excision for low rectal cancer. *Colorectal Dis* 2012;14:e655-60.
3. Chi P, Chen ZF, Lin HM, Lu XR, Huang Y. Laparoscopic extralevator abdominoperineal resection for rectal carcinoma with transabdominal levator transection. *Ann Surg Oncol* 2013;20:1560-6.
4. Feng B, Lu J, Zhang S, Yan X, Li J, Xue P, *et al.* Laparoscopic abdominoperineal excision with trans-abdominal individualized levator transection: Interim analysis of a randomized controlled trial. *Colorectal Dis* 2017;19:O246-52.
5. Nagtegaal ID, van de Velde CJ, Marijnen CA, van Krieken JH, Quirke P; Dutch Colorectal Cancer Group. Low rectal cancer: A call for a change of approach in abdominoperineal resection. *J Clin Oncol* 2005;23:9257-64.
6. West NP, Anderin C, Smith KJ, Holm T, Quirke P; European Extralevator Abdominoperineal Excision Study Group. Multicentre experience with extralevator abdominoperineal excision for low rectal cancer. *Br J Surg* 2010;97:588-99.